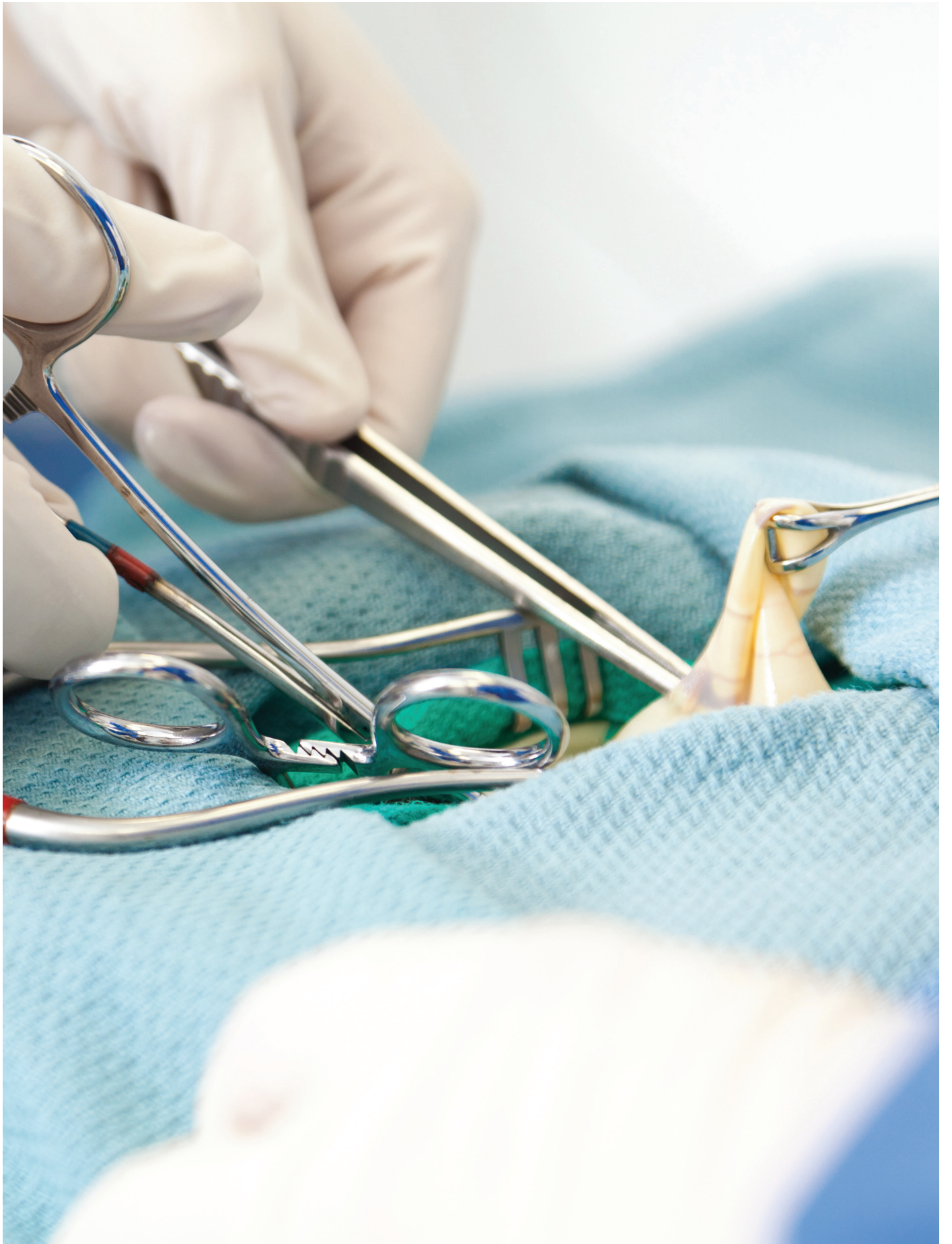



# Laparoscopic Appendectomy Instrumentation

JON WOOD, BAAS, CIS, CRCST – IAHCSSM CLINICAL EDUCATOR

Instrument Continuing Education (ICE) lessons provide members with ongoing education in the complex and ever-changing area of surgical instrument care and handling. These lessons are designed for CIS technicians, but can be of value to any CRCST technician who works with surgical instrumentation.

### Earn Continuing Education Credits:

**Online:** Visit [www.iahcsmm.org](http://www.iahcsmm.org) for online grading at a nominal fee.

**By mail:** For written grading of individual lessons, send completed quiz and \$15 to:  
Purdue University - Online Learning  
Ernest C. Young Hall, Room 526  
155 S. Grant Street  
West Lafayette, IN 47907

**Scoring:** Each quiz graded online at [www.iahcsmm.org](http://www.iahcsmm.org) or through Purdue University, with a passing score is worth two points (2 contact hours) toward your CIS re-certification (6 points) or CRCST re-certification (12 points).

**More information:** IAHCSSM provides online grading service for any of the Lesson Plan varieties. Purdue University provides grading services solely for CRCST and CIS lessons. Direct any questions about online grading to IAHCSSM at 312.440.0078. Questions about written grading are answered by Purdue University at 800.830.0269.

### LEARNING OBJECTIVES

1. Describe the different instrumentation needed to perform a laparoscopic appendectomy
2. Identify key cleaning and inspection points for laparoscopic appendectomy instrumentation
3. Review medical terminology associated with appendectomy procedures
4. Discuss the function of laparoscopic instruments during a laparoscopic appendectomy

A patient walks into the Emergency Department with dull pain around the belly button that radiates and becomes sharper as it moves to the lower right abdomen. The patient reports a loss of appetite and is experiencing some nausea and vomiting. The vital signs show a low-grade fever and the physical exam reveals abdominal swelling and pain upon touching the right lower abdomen. After several tests, the patient is diagnosed with appendicitis.

This lesson will examine instrumentation needed to perform a laparoscopic appendectomy, identify key inspection points, review medical terminology related to the appendectomy procedure and discuss the function of laparoscopic instruments during a laparoscopic appendectomy.

### Objective 1: Describe the different instrumentation needed to perform a laparoscopic appendectomy

Laparoscopic instrument configurations can vary by design, manufacturer,

facility-specific needs, and surgeon preference. The appendectomy procedure requires a mixture of both general instrumentation and laparoscopic instrumentation, which can be arranged in a single instrument tray format or be a combination of several trays, including a minor or basic general instrument tray, laparoscopic instrumentation and telescope tray. The following is a list of common instruments used during a laparoscopic appendectomy:

#### General instrumentation

- Knife handle
- Crile or Kelly clamps
- Allis clamp
- Kocher clamp
- Needle driver
- Metzenbaum scissor
- Mayo scissor
- Forceps with teeth
- Forceps without teeth
- Retractors

#### Laparoscopic instrumentation

- Maryland dissector



Figure 1: Dissected flushing port shows the intersection with the instrument shaft

- Atraumatic “crocodile” grasper
- Metzenbaum scissor
- Right angle/Mixer dissector
- Babcock clamp
- Suction/Irrigator
- Electrosurgical tips or hooks
- Veress needle
- Trocars (various sizes with reducers)
- Monopolar cable

Telescope set

- 5mm telescope 0 degree and 30 degree
- 10mm telescope 0 degree and 30 degree

Camera set

- Laparoscopic camera
- Light cord

\*Available instrumentation

- Major general instrument set
- Abdominal retractor set (Bookwalter or Omni Tract)

\*Note: When performing any laparoscopic procedure, it is advisable to always have

available instrumentation to perform an open procedure.

**Objective 2: Identify key cleaning and inspection points for laparoscopic appendectomy instrumentation**

As with all instrumentation, Central Service/Sterile Processing (CS/SP) professionals should review the instructions for use (IFU) before the instrument is purchased and placed into service. Because there are several different manufacturers and types of laparoscopic instruments, it is important to review the IFU for point-of-use treatment, cleaning procedures, packaging, inspection and sterilization instructions for each instrument, and then periodically review the IFU for changes and updates.

There are three distinct generations of laparoscopic instruments. The first-generation laparoscopic instrument is designed as a single-piece instrument that cannot be disassembled. The



Figure 2: A third-generation “take-apart” laparoscopic instrument

instrument has a handle, shaft, distal working end and, possibly, an electrocautery port for tissue cauterization. The second-generation instrument is similar in many ways to the first-generation instrument, except for the presence of a flushing port. The flushing port begins proximal to the handle and runs through the inner shaft of the instrument to the distal working end. The flushing port is an added feature designed to aid in the cleaning of the instrument. If the instrument is not treated at the point of use, the shaft can fill with dried bioburden and become difficult to flush, thereby requiring extended soaking times to loosen debris. Figure 1 shows the flushing port dissected to visualize the intersection with the instrument shaft. The third-generation instrument is a take-apart instrument, meaning it can be disassembled into several parts (see Figure 2). It is important to disassemble these instruments when cleaning to ensure all bioburden is removed from the instrument. Keeping the instrument parts together during the cleaning process allows for a smoother assembly process. Before sterilization, it is important to read the IFU to determine whether the instrument can be sterilized assembled or disassembled.

After the cleaning process, every laparoscopic instrument should be visually inspected for damage and tested for current leaks, which indicate a breach



**Figure 3:** Current leak testers help identify insulation breaches that can jeopardize patient safety.

in the insulation. The manufacturer's IFU for insulation testing should be followed. Figure 3 shows a current leak tester in use.

Most cameras, light cords and telescopes must be hand washed and should not be cleaned using an ultrasonic or automated washer disinfectant. It is essential to rinse the devices with critical water to remove any excess mineral deposits, which can potentially interfere with the different sterilization modalities.

After cleaning, the camera, light cord and telescope should be carefully inspected. This step is critical because once the CS/SP technician has inspected

the devices, the devices will not be seen again until they are opened in the Operating Room (OR). The best method for inspecting these devices for functionality is to insert the devices into a laparoscopic tower, like the towers used in the OR. Using a laparoscopic tower allows the CS/SP technician to simulate the conditions in the OR when checking the devices to ensure they are working properly. When checking the camera, it is important to ensure the camera can focus when zooming in and out, and that it produces a clear image. Spots on the lens must be removed because their presence can blur the image viewed by the

surgeon. Buttons should be checked for functionality, including the white balance button. The white balance button gives the camera a reference to true white. A malfunctioning button can turn video images blue or yellow, making it difficult for the surgeon to visualize different structures within the abdomen.

Some facilities may not have access to a laparoscopic tower and the ability to plug in and check devices. In this case, a manual check of the devices should be performed. For example, when checking the light cord, the technician can raise one end of the light cord in the air toward a light source, while visually



Figure 4: A light cable with broken fibers

inspecting the other end and looking for broken fiber optics. Broken fibers will appear as black dot or specks and will not be illuminated. Because the fibers are made of glass, they are very fragile and should be handled with care. Most light cords that have been used for any amount of time will have several broken fibers. A small amount of broken fibers may not affect the light output from the cable; however, when too many fibers are broken, the light output can start to diminish and the cord should be replaced. Figure 4 shows a light cable with broken fibers.

Like the light cord, the telescope fiber optics should be inspected to ensure adequate light output. Both the lens from the eyepiece and the distal working lens should be inspected for scratches, chips, cracks or other damage. A classic sign of damage to a telescope is the dark, half-crescent moon shape in the image of the endoscope, which can indicate a broken

glass rod.

### Objective 3: Review medical terminology associated with appendectomy procedures

- Appendectomy – Removal of the appendix
- Eschar – A thick, coagulated crust that develops following physical cauterization of tissue
- Laparoscopy – A minimally-invasive surgical technique in which a lighted scope (laparoscope) is inserted into a small incision in the abdomen
- Left lower quadrant (LLQ) – The portion of the abdomen that contains part of the descending colon, sigmoid colon, left ovary and tube, and left ureter (see Figure 5)
- Left upper quadrant (LUQ) – The portion of the abdomen that contains the stomach, spleen, left lobe of the liver, body of the pancreas, left kidney and splenic flexure of the colon (see Figure 5)

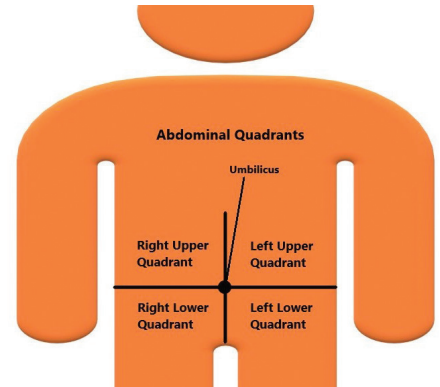


Figure 5: The four quadrants of the abdomen

- Mesentery – The membranous peritoneal ligament that attaches the small intestine to the dorsal abdominal wall
- Mesoappendix – The short mesentery of the appendix (behind the terminal ileum in which the appendicular artery lies)
- Pneumoperitoneum – The presence of air or gas produced artificially in the abdomen to achieve exposure during laparoscopic surgery
- Right lower quadrant (RLQ) – The portion of the abdomen that contains the caecum, appendix, right ovary and tube, and right ureter (see Figure 5).
- Right upper quadrant (RUQ) – The portion of the abdomen that contains the liver, gallbladder, duodenum, head of the pancreas, right kidney and hepatic flexure of the colon (see Figure 5)
- Suprapubic – The area above the pubic bone

### Objective 4: Discuss the function of laparoscopic instruments during a laparoscopic appendectomy

After the patient is anesthetized, the patient is then prepped and readied for surgery. The patient is draped and the surgical technologist, with the help of the registered nurse circulator, begins laying out the camera and light cord and



plugging them into the tower. Once the light cord is activated, any breaches in the light cord with exposed fiber optics can quickly become a fire hazard. The energy produced by the light source can rapidly heat exposed fiber optics, making them an ignition source, and can then use the drapes as fuel for a fire. A thorough inspection of the cords' integrity in the CS/SP area can prevent surgical fires and patient burns.

Next, a pneumoperitoneum is achieved by introducing carbon dioxide gas through a Veress needle or by using an umbilical trocar. It is important to ensure the valves that control the flow of carbon dioxide gas through the Veress needle or trocars remain open prior to sterilization. A closed valve can impede the flow of steam through the valve and can potentially remain unsterile through the sterilization process.

Small skin incisions are then made and fascial layers are dissected down to the peritoneum. One trocar is then placed in the umbilicus (site for the laparoscope), the second trocar is placed in the right upper quadrant (RUQ) and is considered the working port, and the third is placed in the midline suprapubic site. The size of the trocars depends on the size of the patient and the instrumentation the surgeon will use. Trocars should be accompanied with reducers, which allow 5mm and 10mm instrumentation to be interchanged through the ports. Trocars and reducers use O-rings and seal caps with miniature holes in the center that allow instrumentation to pass through the trocar, while still maintaining a positive pneumoperitoneum. The seal caps and O-rings must be checked for cracks or integrity failures. The failure of the seal cap or O-ring could allow carbon dioxide gas to escape, causing the abdomen to deflate and the surgeon to lose the field of vision.

A laparoscopic Babcock is placed in

the RUQ port site and is used to grasp the cecum and retract it toward the liver.

*Note: Any dirty instrument that enters the abdominal cavity has direct access to vital organs, such as the liver and kidneys, and can potentially cause an infection. It is imperative to inspect the small cervixes and joints of the distal working ends of the instrument to help prevent infection. The appendix is then identified and grasped with a non-traumatic grasper through the suprapubic trocar port.*

The Babcock is removed and a dissecting instrument (like the Maryland dissector) is inserted in the RUQ port to create a window in the mesoappendix. Dissection is then performed to isolate the appendicular artery. A clipping device is used to apply clips to the artery, and the vessel is divided with scissors that have electrocautery capabilities. Performing electrocautery in the abdomen presents another opportunity where the patient can have a serious complication. If there is a breach in the electrocautery insulation, electricity can pass through the breach and burn unintended structures, leading to tissue damage and, potentially, an infection. Therefore, current leak testing is an important part of the inspection process.

The appendix is then transected with either a stapling device, ligating loop or suturing device. The remainder of the mesoappendix is dissected and hemostasis is achieved with closed scissor tips or an electrocautery hook. Any time electrocautery is used, the burnt tissue or eschar can adhere to the cautery site of the instrument and make the instrument less effective. Generally, eschar will appear or leave a black mark on the end of the instrument. The tissue must be removed as soon as possible on the surgical field using a scratch pad, and any black staining residual can be removed with a bristle brush in the decontamination room.

After the appendix is transected, the laparoscope is removed from the umbilicus port and moved to the suprapubic port. An endo-bag is then placed in the umbilicus trocar port and the appendix is retrieved and removed. The abdomen is then irrigated using a suction irrigator, and the trocar ports are removed under visualization. The incisions are then closed using an Adson forceps and a needle driver. Fascia is closed with 4-0 vicryl suture and skin is closed with 5-0 monocryl suture or with a skin-bonding sealer. *Note: There are several variations of the laparoscopic appendectomy procedure. This fourth objective covers some, but not all, surgeon-specific instrument preferences or procedure styles.*

### Conclusion

The laparoscopic appendectomy procedure could not be successful without the knowledge and due diligence of the CS/SP instrument technician. CS/SP technicians who understand the importance of instrument inspection and testing and are familiar with how instrumentation is used during a procedure are better equipped to prevent adverse patient outcomes. 📍

### RESOURCES

Alexander's. *Care of the Patient in Surgery*. Chapter 10. *Gastrointestinal Surgery*, pp. 341. 2011.

International Association of Healthcare Central Service Materiel Management. *CSSD Dictionary and Reference Guide*. 2010.

International Association of Healthcare Central Service Materiel Management. *Instrument Resource Manual, Chapter 18 Laparoscopic Instrumentation*. 2018.

Stedman's Medical Dictionary for the Health Professions and Nursing. 2006.



# CIS Self-Study Lesson Plan Quiz - Laparoscopic Appendectomy Instrumentation

Lesson No. CIS 275 (Instrument Continuing Education - ICE) • Lesson expires September 2022

- Which of the following instruments would most likely not be found in a laparoscopic appendectomy set?
  - Hurd dissector and Pillar retractor
  - Maryland dissector
  - Metzenbaum scissor
  - Babcock clamp
- All laparoscopic instrumentation is similar, so it is not necessary to have the instructions for use available from each manufacturer whose instruments are represented in the facility laparoscopic tray.
  - True
  - False
- Which generation of laparoscopic instruments cannot be disassembled and has a flushing port?
  - First generation
  - Second generation
  - Third generation
  - Fourth generation
- Which generation of laparoscopic instruments can be disassembled into several parts?
  - First generation
  - Second generation
  - Third generation
  - Fourth generation
- The flushing port:
  - Is designed to aid in the cleaning of the instrument
  - Begins proximal to the handle and runs through the inner shaft of the instrument to the distal working end
  - Is located distally to the handle
  - Both A and B
- Cameras, light cords and telescopes cannot be checked for functionality without the use of a laparoscopic tower.
  - True
  - False
- Which button on the camera gives the camera a reference to true white?
  - Auto focus
  - Color balance
  - White balance
  - White focus
- The presence of gas in the abdomen is referred to as:
  - Anesthesia
  - Pneumoperitoneum
  - Mesoappendix
  - Laparoscopy
- A thick, coagulated crust that develops following physical cauterization of tissue is called:
  - Pneumoperitoneum
  - Mesoappendix
  - Biofilm
  - Eschar
- The membranous peritoneal ligament that attaches the small intestine to the dorsal abdominal wall is called the:
  - Pneumoperitoneum
  - Mesoappendix
  - Mesentery
  - Suprapubic
- The appendix can be found in which of the four abdominal quadrants?
  - Left lower quadrant
  - Left upper quadrant
  - Right lower quadrant
  - Right upper quadrant
- The left lobe of the liver can be found in which of the four abdominal quadrants?
  - Left lower quadrant
  - Left upper quadrant
  - Right lower quadrant
  - Right upper quadrant
- Which of the following is not a trocar port site discussed in the lesson?
  - Right lower quadrant
  - Right upper quadrant
  - Umbilicus
  - Midline suprapubic
- Which instrument is used to grasp the cecum and retract it toward the liver?
  - Atraumatic "crocodile" grasper
  - Metzenbaum scissor
  - Right angle/Mixer dissector
  - Babcock clamp
- Where should a bristle brush be used to remove black staining from an electrocautery hook?
  - In the Operating Room
  - In the decontamination area
  - In the preparation and packaging area
  - In the sterile storage area

**Request for online scoring** (payment and scoring made directly online at [www.iahcsmm.org](http://www.iahcsmm.org))

**Request for paper/pencil scoring** (please print or type information below)

- I have enclosed the scoring fee of \$15. (please make checks payable to Purdue University. We regret that no refunds can be given)
- Check here if you have a change of address
- Check here if you wish to have your results emailed to you

**Detach quiz, fold, and return to:**

Purdue University - Online Learning  
Ernest C. Young Hall, Room 527  
155 S. Grant Street  
West Lafayette, IN 47907  
800.830.0269

Name \_\_\_\_\_

Mailing Address (be sure to include apartment numbers or post office boxes) \_\_\_\_\_

City \_\_\_\_\_ State/Province Zip Code/Postal Code \_\_\_\_\_

( ) Daytime telephone \_\_\_\_\_ IAHCSSM Membership Number \_\_\_\_\_

Email Address \_\_\_\_\_

*If your name has changed in the last 12 months, please provide your former name  
Purdue University is an equal access/equal opportunity institution*